



## AN OVERVIEW OF FOCAL DUODENAL NECROSIS (FDN)

### BACKGROUND

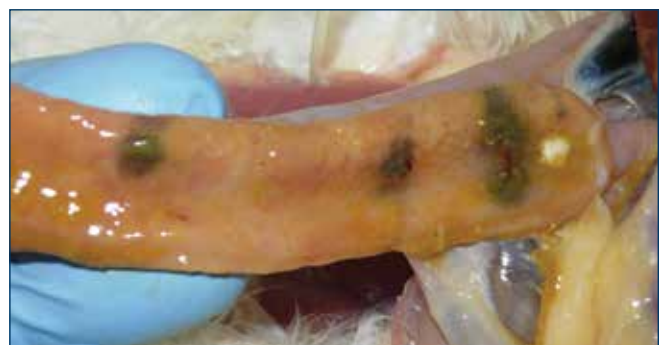
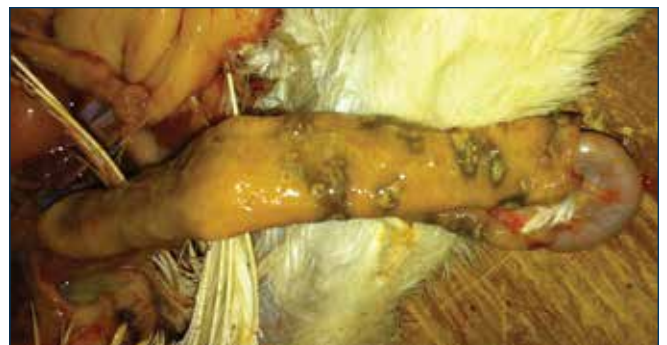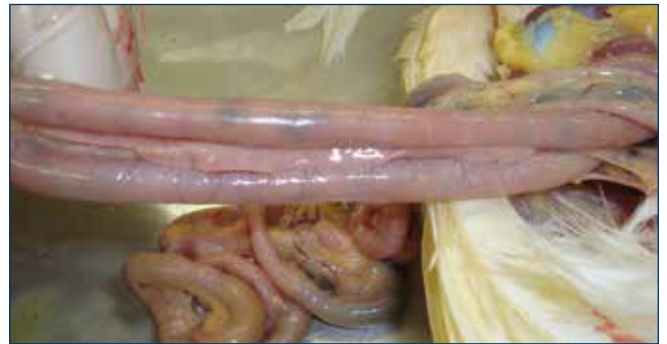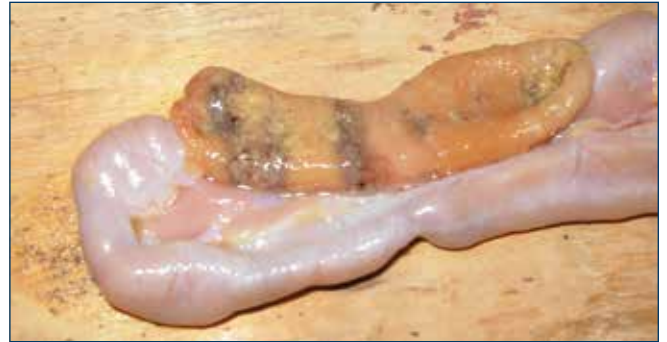Focal duodenal necrosis (FDN) is a poorly understood intestinal disease syndrome first described in egg layer chickens in 1997 by Dr. Patricia Dunn at Pennsylvania State University. This disease is also known as multifocal ulcerative duodenitis and generally as “gray gut.” It has been observed in cage, cage-free and organic flocks of both brown and white egg layers of all major genetic suppliers. FDN has been diagnosed in the United States and Europe. Most often, FDN is found in multi-age complexes and in flocks housed in facilities with manure belts.

The only observable clinical sign in birds is pale combs. In contrast to other common enteric diseases, livability of the flock is not affected and the droppings appear normal. FDN has been diagnosed in flocks from 15 week old pullets until end of lay.

FDN does have important economic impact. Flocks with FDN have reduced egg weights (as much as 2.5 g per egg / 2 lbs per case) and egg production may be below standard by up to 10%. Body weight gains up to 32 weeks, or body weight maintenance after peak may be negatively affected. Decreased absorption of calcium due to a damaged duodenum may also affect shell quality and skeletal integrity.

### DIAGNOSIS

FDN causes observable lesions in the duodenum and less frequently the first section of the jejunum. Lesions include ulcerations and/or gray-green patches in the mucosa of the intestines. These dark patches may be single to multiple, irregularly shaped, 5-15 mm diameter areas. It has been documented that microscopic ulcerations were observed on the tips of the villi, usually populated with large Gram-positive bacteria and heterophilic inflammation. The intestinal lesions may produce hydrogen sulfide gas, giving a “rotten-egg smell” during post-mortem examination. Even birds without observable lesions may have subclinical lesions as observed by histopathology.



*Images courtesy of Dr. Eric Gingerich, 2012*

## DIAGNOSIS continued

The typical lesions in the duodenum disappear rapidly after death. Diagnosis can only be made by observing the characteristic lesions upon necropsy of birds within an hour of expiration. Necropsy of birds with pale combs may increase the likelihood of finding FDN. Monitoring a small random sample of birds for FDN should be done on a regular schedule of every 4 to 8 weeks. Routine necropsy of birds on a poultry farm is the most effective way to monitor flocks for enteric diseases or other health and nutritional issues. Early observation will ensure that appropriate treatments can be utilized prior to excessive mortality or production issues.

Due to the observable and histopathological lesions, it is highly likely that FDN interferes with the normal digestive process. The duodenum, while physiologically important for nutrient digestion, is not a region where high amounts of nutrient absorption occur compared to the ileum and jejunum. However it may be noteworthy that the duodenum is a significant site of hormone-regulated active calcium absorption in laying hens. Any damage to the cells in the duodenum could be expected to impair overall calcium absorption, thereby having potential consequences for bone and shell mineralization. Additionally the duodenum is a major region of iron absorption which might explain the pale combs and possible anemia of severely or chronically affected birds.

There has been no proven cause of FDN although it is closely associated with *Clostridium* infection. A current theory is that *Clostridium colinum* grows in the intestines and produces toxins that create the FDN lesions. There is additional evidence that *Clostridium perfringens* may also be linked with FDN.

## PREVENTION AND TREATMENT

It appears that most antibiotics that are effective against Gram-positive anaerobic bacteria will efficiently treat FDN. The most useful antibiotics are those with a zero day withdrawal for egg production, which will vary by country. In the USA, bacitracin (BMD) at 25g per ton of feed is the most common and successful treatment. In Europe and the USA, other antibiotics including oxytetracycline, chlortetracycline, penicillin, neomycin, tylosin, and erythromycin have been used.

Treatment usually involves administering antibiotics until the standard egg weights are restored and FDN lesions are no longer observed. Even after successful treatment and recovery of affected flocks, relapse and recurrence of the disease is possible 6-8 weeks after treatment.

Investigations are ongoing to determine if probiotics and organic acids may be used to help reduce the risk of FDN.

## REFERENCES

- "Disease Perspectives in Pullets and Layers for the Midwest and West Coast"; Proceedings of the "Midwest Poultry Federation Convention." St. Paul, MN. Jan. 2008. Drs. Bernie Beckman, Doug Grieve and Kenton Kreager, Hy-Line North America, Hy-Line International.
- "Reducing the Risk of Focal Duodenal Necrosis (FDN) in Table Egg Flocks"; Nutrition Line 2010, Dr. Eric Gingerich, Diamond V.
- "NetB-producing and beta2-producing *Clostridium perfringens* associated with subclinical necrotic enteritis in laying hens in the Netherlands"; Avian Pathology, 41:6 pages 541-546. Janneke G. Allaart, Naomi D. de Bruijn, Alphons J. A. M. van Asten, Teun H. F. Fabri and Andrea Gröne. 2012



Hy-Line International | [www.hyline.com](http://www.hyline.com)

